

REVIEW

Open Access



# Bile cast nephropathy: when the kidneys turn yellow

Alissar El Chediak<sup>1†</sup>, Khaled Janom<sup>2†</sup> and Sahar H. Koubar<sup>3\*</sup>

## Abstract

Kidney injury is a common finding in patients with liver disease. Bile cast nephropathy (also known as cholemic nephropathy) is an overlooked cause of renal injury in patients with hyperbilirubinemia. It can occur as a result of the toxic effects of bilirubin and bile acids on the renal tubules via several mechanisms. Bile cast nephropathy has characteristic histopathological changes consisting of bilirubin cast deposition in the distal nephron along with tubular epithelial cell injury. Treatment is based on the reversal of liver injury. This review aims to describe bile cast nephropathy in terms of its clinical and morphological features and to shed light on diagnostic techniques. In addition, we present data on management of such nephropathy while reviewing all the reported cases of bile cast nephropathy.

**Keywords:** Bile cast nephropathy, Cholemic nephropathy, Hyperbilirubinemia, Extracorporeal therapy

## Introduction

Bile cast nephropathy is a form of acute kidney injury (AKI) manifesting in patients with severe direct hyperbilirubinemia [1]. It is a rare entity that is often thought of last when it comes to explaining an AKI. It is also known as cholemic nephropathy, bile acid nephropathy, biliary nephrosis, and jaundice related nephropathy [1–3].

It was initially described by Qunicke in 1899 in autopsy studies of patients with acute jaundice and renal insufficiency [2, 4]. Later in 1922, Haessler et al. showed that biliary salt sediments were found in the urine of dogs and humans with jaundice, and that the amount of sediments decreased as jaundice resolved [1, 3–5]. The gold standard for diagnosing this entity is renal biopsy.

The prevalence of bile cast nephropathy is probably underestimated as pathological diagnosis is often missing considering the increased bleeding risk of renal biopsy in

coagulopathic patients with liver disease; however, it has been recognized more frequently lately with the utilization of transjugular renal biopsy [1, 2, 5, 6]. Nonetheless, Nayak et al. conducted a study on postmortem kidney biopsy [7]. Their aim was to investigate the frequency of bile cast nephropathy detected on postmortem renal biopsy among patients with decompensated cirrhosis who had been admitted with AKI due to hepatorenal syndrome. They were able to detect bile cast nephropathy in 44.8% of all the postmortem renal biopsy specimens and in 72.1% of the patients with acute on top of chronic liver failure. So, it is imperative to recognize this entity early, as directed treatment and management may lead to a better prognosis [2].

## Pathophysiology of bile cast nephropathy

Bile cast nephropathy is suspected in the setting of an acute kidney injury with concomitant direct hyperbilirubinemia. Normally, most bile acids are reabsorbed in the ileum and then transported back to the liver via portal blood circulation to inhibit bile acid synthesis [8]. Small amounts of bile acids are recovered in kidney [8]. Renal-hepatic circulation of bile salts is via organic solute

\* Correspondence: [sk62@aub.edu.lb](mailto:sk62@aub.edu.lb)

†Alissar El Chediak and Khaled Janom contributed equally to this work.

<sup>3</sup>Department of Internal Medicine, Division of Nephrology, Faculty of Medicine, American University of Beirut, PO-BOX: 11-0236, Riad El Solh, Beirut 1107 2020, Lebanon

Full list of author information is available at the end of the article



© The Author(s). 2020 **Open Access** This article is licensed under a Creative Commons Attribution 4.0 International License, which permits use, sharing, adaptation, distribution and reproduction in any medium or format, as long as you give appropriate credit to the original author(s) and the source, provide a link to the Creative Commons licence, and indicate if changes were made. The images or other third party material in this article are included in the article's Creative Commons licence, unless indicated otherwise in a credit line to the material. If material is not included in the article's Creative Commons licence and your intended use is not permitted by statutory regulation or exceeds the permitted use, you will need to obtain permission directly from the copyright holder. To view a copy of this licence, visit <http://creativecommons.org/licenses/by/4.0/>. The Creative Commons Public Domain Dedication waiver (<http://creativecommons.org/publicdomain/zero/1.0/>) applies to the data made available in this article, unless otherwise stated in a credit line to the data.

transporters in the proximal tubules [9]. During cholestasis, there is an upregulation of the hepatocytic basolateral bile acid pumps in an attempt to excrete the excess direct bilirubin into the blood [2]. With hyperbilirubinemia, the kidneys will adapt by excreting the excess bile acids, mainly in the proximal convoluted tubules; in fact, it has been reported that in some cases the renal clearance of bilirubin increases from below 5% to almost 90% [2, 10].

Bilirubin excess has deleterious effects on many fronts when it comes to the kidneys. Bilirubin exerts an oxidative stress on the tubules leading to damage of the tubular cell membranes [1–3, 11]. This damage could lead, in some patients, to tubular cell hypertrophy [3, 11, 12]. This was observed in 73.5% of autopsies performed on jaundiced individuals [13]. Holmes' autopsies demonstrated swelling of the tubular epithelium, pigmented casts, hypertrophy, and hyperplasia of the parietal layer of Bowman's capsule [13]. Similar to the changes seen in diabetic nephropathy, tubulointerstitial hypertrophy is the most likely precursor of later irreversible changes in the tubulointerstitial architecture leading to tubular atrophy and interstitial fibrosis [14]. Bilirubin also inhibits mitochondrial oxidative phosphorylation leading to more damage to the tubular cells with subsequent decrease in adenosine triphosphate activity [2, 15–17]. Such a decrease leads to mitochondrial defects with increased penetration of cell membranes resulting in modified electrolyte content and cell volume [17]. Particularly, bile acids have been reported to cause inhibition of  $\text{Na}^+/\text{H}^+$ ,  $\text{Na}^+/\text{K}^+$ , and  $\text{Na}^+/\text{Cl}^-$  transporters resulting in alterations in the pH in the tubules and contributing to an acidic milieu that favors cast formation [2, 6, 15, 18]. To note, however, bilirubin contains neither heme nor iron; both of which have been associated with kidney injury [15].

The key finding in this disease entity is the tubular obstruction and injury caused by the bilirubin cast formation within the distal kidney tubules, a mechanism that mimics the damage in myeloma cast nephropathy [11, 19]. Bile salts have low solubility in water, and normally when filtered by the glomerulus, they are transported by the proximal tubules back into the circulation [3, 20]. In the case of extreme hyperbilirubinemia, these transporters will be saturated, thus causing the tubules to be over flooded with bilirubin, a key factor to enhance cast formation and subsequently tubular obstruction, especially with increased acidity in the distal nephron [2, 3, 10, 21].

Another mechanism by which hyperbilirubinemia has been associated with kidney injury is via its effect on systemic and renal hemodynamics. In fact, studies in mice have shown that excess bilirubin exerts negative inotropic and chronotropic effects on the heart, leading to a

decrease in kidney perfusion [2, 15, 18, 22]. The depressed cardiac performance is occasionally termed "jaundiced heart" by some authors and is expected to improve after resolution of the hyperbilirubinemia [23, 24]. It is also proposed that the lack of enteral bile acids results in systemic endotoxemia and subsequently hypotension and a low perfusion state [1, 2, 22]. Thus, hyperbilirubinemia is related to marked splanchnic and systemic vasodilatation that results in a lower glomerular filtration rate contributing to kidney injury [3, 25].

In summary, the kidney injury in bile cast nephropathy can be due to the following mechanisms: tubular epithelial injury, basement membrane effects causing tubular leakage and obstruction, and hemodynamic changes affecting both the kidneys and the systemic circulation.

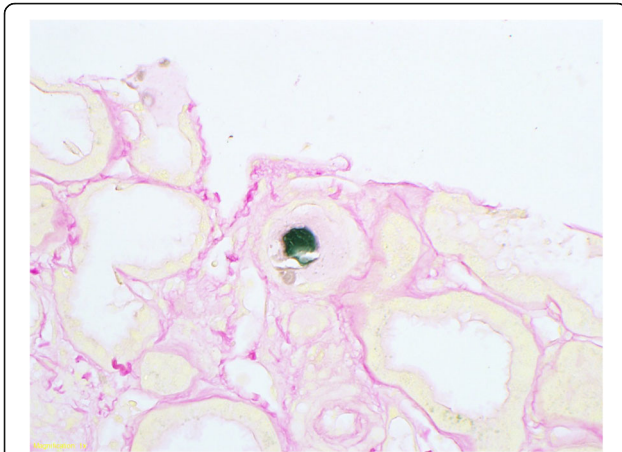
An *in vivo* model using common bile duct ligation (CBDL) in mice has been proposed to describe the mechanism of kidney injury in cholemic nephropathy [16]. CBDL induced renal tubular epithelial injury occurred predominantly at the level of aquaporin 2-positive collecting ducts with tubular epithelial and basement membrane defects as early as day 3 [16]. This was followed by interstitial nephritis and progressive tubulointerstitial renal fibrosis at 3, 6, and 8 weeks [16].

### Pathology

Macroscopically, the kidney's cortex and medulla of patients with hyperbilirubinemia appear yellow due to the presence of bilirubin and bilirubin casts. After treatment of these kidneys with formalin fixation, the bilirubin will be converted to biliverdin and the color changes from yellow to green [1, 3]. The green color is more prominent in the medulla due to the presence of higher cast concentration in the distal nephrons [1, 3].

The pathology induced by the excess bilirubin is mainly limited to the tubules [1, 3, 16]. Light microscopy and immunofluorescence would show no glomerular abnormalities [4, 10, 26]. Many case reports of kidney biopsies have demonstrated bilirubin cast deposition mainly in the distal renal tubules and minimally in the proximal tubules [12, 15, 27]. A clinico-pathologic study done by van Slambrouck et al. on 3 renal biopsies and 41 autopsy studies of patients with jaundice showed distal deposition of bile casts in more than 50% of them, while only 6 biopsies had proximal tubular involvement [1, 3, 5]. The degree of bile cast formation correlated significantly with the severity of jaundice [1, 3].

Bile casts are formed of sloughed epithelial cells and acellular material. Thus, they can be identified by the Hall stain which detects bilirubin [17]. This stain utilizes Fouchet reagent, which converts bilirubin to biliverdin thus yielding a green color (Fig. 1) [1, 10, 28, 29]. Iron stain in these cases is negative indicating the absence of heme.



**Fig. 1** Bile casts visualized by Hall stain (Courtesy of Dr. Samih Nasr)

Acute tubular necrosis (ATN) is a prominent feature of biopsies of patients with bile cast nephropathy. Several case studies have reported ATN as a feature in the biopsy [10, 19] (Table 1). Pathological features include loss of tubular brush borders, attenuated cytoplasm of tubular cells, dilatation of the tubular lumen, cytoplasmic vacuolization, apical blebbing, and tubular necrosis and desquamation [2, 4, 19, 28]. In the study done by van Slambrouck, ATN was noted in 76% of the biopsies [3, 5, 15, 26].

Another key finding on kidney biopsy in patients with bile cast nephropathy is hypertrophy of the tubules [2, 3, 12]. Immunofluorescence and electron microscopy studies show no abnormalities [4].

### Approach and diagnosis

The diagnosis of bile cast nephropathy can be made clinically when other causes of AKI have been ruled out. The definitive diagnosis is via a kidney biopsy; however, a transcutaneous kidney biopsy carries higher risk of bleeding in those coagulopathic patients, and so it is seldom performed. Moreover, since the pathology of bile cast nephropathy is mainly evident in the distal nephron, we may argue that a conventional kidney biopsy (which reaches the cortex) might not reach these segments. A trans-jugular renal biopsy (TJRB) approach might be a reasonable alternative. Four hundred patients underwent TJRB and were compared to four hundred patients who underwent percutaneous renal biopsy [42]. They reported a diagnostic tissue adequacy of 95.8%, with a major complication rate of 1% [42]. Sam et al. described their experience with TJRB in 29 patients with coexisting kidney and liver diseases [43]. They concluded that TJRB appears to be a safe and effective procedure for establishing a histological diagnosis in patients with advanced liver disease and contraindications to conventional percutaneous renal biopsy.

The diagnosis of bile cast nephropathy can be strongly suspected when urinalysis shows bile crystals [12]; although their role in the pathophysiology of the disease remains unclear [2, 10–12]. In some cases, granular casts have been reported due to the role of ATN in the pathophysiology of bile cast nephropathy [11]. Hyperuricosuria also develops because bilirubin is said to inhibit the absorption of uric acid in the proximal tubules [12]. Potassium wasting also occurs and is consistent with the tubular injury caused by the bilirubin casts.

### Treatment and outcome

Treatment of bile cast nephropathy depends on prompt management of hyperbilirubinemia to avoid kidney damage. Several case studies reported reversal of kidney injury with reduction of bile acid and bilirubin levels, though at different recovery rates [10–12, 28]. We compiled a summary of the clinical and pathological characteristics of all biopsy proven bile cast nephropathy reported in literature since 2000 along with the management modalities used (Table 1). We also included the different outcomes with each treatment used in that table.

Extensive initial injury has been associated with delayed recovery [3, 12, 28]. Currently, there are no accepted treatment guidelines; rather, there is a focus on decreasing bilirubin levels and reversing the cause of the liver injury. In case of biliary stones or tumors for instance, endoscopic retrograde cholangiopancreatography with or without stenting is used to relieve the obstruction. Removal of excess bilirubin and bile acids has been carried out by extracorporeal therapies.

Extracorporeal therapies for bile cast nephropathy are divided into two major groups: biologic and non-biologic (Fig. 2) [44]. Biological devices use living liver cells (human or porcine) to support the failing liver through detoxification and synthetic function [45]. Non-biologic devices use artificial membranes and adsorbents for detoxification [44]. These include plasmapheresis and albumin dialysis.

Plasmapheresis can be utilized to remove the excess toxins and bilirubin in persistent cholestasis to improve the symptoms and the outcomes [26]. Not only that, it replenishes albumin, coagulation factors, and hepatic regenerative stimulating substances [46]. Plasmapheresis is mostly mentioned in the literature for the management of liver failure [46–49]. Keklik et al. published their experience with plasma exchange as a treatment for patients with severe hyperbilirubinemia [48]. They observed a statistically significant decline in total and direct bilirubin levels after plasma exchange [48]. A case of steroid induced bile cast nephropathy that was treated with plasma exchange was also reported by El Khoury et al. [50].

**Table 1** Summary of the clinical and pathological characteristics of all biopsy proven bile cast nephropathy reported in literature since 2000

Author	Age (year)/ Gender	Primary disease	Bilirubin level (mg/dL)	Peak creatinine (mg/dl)	Biopsy findings	Therapies used	Outcome
Bal et al. [30]	NA (3 cases)	Subacute hepatic failure	20 (T)	–	Mesangial proliferation and thickening, basement membrane thickening, presence of hyaline, granular and bile casts	–	–
Kiewe et al. [31]	40/F	Hodgkin's lymphoma	30.4 (D)	1.7	Hypertrophy of tubular epithelium Bile casts in distal and collecting tubules	Hemodialysis	Resolution of kidney injury and discontinuation of hemodialysis
Betjes et al. [32]	NA (2 cases)	Obstructive jaundice in patient A, autoimmune hepatitis in patient B	36.2 (T) 33.2 (T)	–	Bilirubin pigment in the tubules Tubular cell necrosis	–	Improvement of renal function along with decrease in bilirubin level in patient A Patient B died
Uslu et al. [33]	NA (20 cases)	Obstructive jaundice	10.1 (T)	–	Dilatation of peritubular venules, acute tubular necrosis	–	Absolute recovery of renal function in all patients after biliary drainage
De Fijter et al. [10]	38/M	EBV infection	28.5 (D)	3.25	ATN features Abundant bile casts	Hemodialysis	Resolution of infection and hyperbilirubinemia Discontinuation of hemodialysis
Burbach et al. [15]	46/M	Cholangio-carcinoma	20.9 (D)	6	Presence of tubular damage: loss of brush border, tubular necrosis Bile casts and thrombi in proximal and distal tubules	Renal replacement therapy	Patient passed away
Van Slambrouck et al. [3]	NA (24 cases)	Obstructive cholestasis	24.9 (T)	–	Bile casts with involvement of distal nephron segments	–	–
Castano et al. [19]	41/M	Anabolic steroid abuse	7.9 (T)	2.9	Multiple green-brown casts in the distal tubules Diffuse ATN with dilatation of tubular lumen, vacuolization of tubular cell cytoplasm, and apical blebbing	No hemodialysis	Kidney function improved over 4 months and Cr plateaued at 1.8 mg/dL
Van der Wijngaart et al. [11]	73/M	Obstructive jaundice with multiple gallstones in the common bile duct	39.6 (T)	7.35	Bile casts, reactive changes of tubular epithelial cells	Hemodialysis, biliary drain	Improvement of kidney function after 5 weeks
Tabatabaee et al. [34]	30/M	Stanozolol abuse	28 (D)	8.7	Preserved glomeruli Degeneration of cortical tubules Bile casts present in some tubules	Hemodialysis	Cr level decreased to 2.5 mg/dL in 2 months
	43/M	Stanozolol abuse	45 (D)	5.4	ATN, bile pigment deposition	Hemodialysis	Cr decreased to 1.8 mg/dL at 2 months
Alkhunaizi et al. [35]	28/M	Anabolic steroid abuse	29.9 (D)	2.6	Glomeruli unremarkable Acute tubular injury with luminal ectasia Dark green bile casts within tubular lamina	Supportive care only, no dialysis	At 3 month follow up: Serum Creatinine returned to normal at 1.1 mg/dL Serum total bilirubin dropped to 1.8 mg/dL
Sequeira and Gu [28]	41/F	Acute alcoholic hepatitis	20 (D)	9.2	Normal glomeruli Intra-tubular bile casts shown by Hall's Stain	Hemodialysis	Urine output improved gradually, however patient continued to need dialysis for poor clearance
Kshiragar et al. [36]	55/M	Colorectal cancer metastatic to liver	25 (D)	2.72	Intratubular bile casts	–	–
Alalawi [12]	61/F	Acute liver injury	7 (T)	7.3	Positive Fouchet stain indicating presence of Bilirubin casts	7 sessions of hemodialysis	Recovered kidney function Discharge Cr = 1.1 mg
Flores et al. [37]	31/M	Anabolic steroid induced cholestasis	53 (T)	2.3	Yellow, brown intraluminal tubular casts Flattening and simplification of the epithelial lining	5 sessions of plasmapheresis No hemodialysis	Bilirubin level decreased Cr level decreased and patient recovered kidney function
Alnasrallah et al. [4]	60/M	Flucloxacillin induced liver injury	34 (D)	6.6	Normal Glomeruli Positive bile stain and bile casts in tubules	No hemodialysis	Bilirubin level decreased Cr level decreased to stabilize at 1.85 mg/dL
Sens et al. [26]	37/M	TCF 2 Mutation induced biliary duct dystrophy	15.2 (D)	5.8	Acute tubular injury: dilated tubules with flattened epithelium Greenish-brown intraluminal casts	Hemodialysis 9 ECAD:1 MARS and 8 SPAD sessions	Patient underwent simultaneous liver kidney transplant
Patel et al. [2]	54/M	Acute liver injury	29 (T)	5.47	Proximal and distal tubules containing bile casts	Hemodialysis	Patient underwent simultaneous liver and kidney transplant Normalization of kidney and

**Table 1** Summary of the clinical and pathological characteristics of all biopsy proven bile cast nephropathy reported in literature since 2000 (Continued)

Author	Age (year)/ Gender	Primary disease	Bilirubin level (mg/dL)	Peak creatinine (mg/dl)	Biopsy findings	Therapies used	Outcome
Werner et al. [38]	76/M	Painless jaundice due to cholangiocellular carcinoma	–	–	Dilated tubules, bile casts	bile duct stent, Hemodialysis	hepatic indices Resolution of renal function after restoration of cholestasis
Mohapatra et al. [39]	NA (20 cases)	Severe falciparum malaria complicated with jaundice	26.5 (T)	–	Numerous tubular casts, acute tubular necrosis but maintained glomerular architecture	–	Recovery time of renal dysfunction 15.1 ± 6.5 days
Leclerc et al. [40]	78/M	Drug-induced hepatic jaundice	30.93 (T)	7.1	Brown casts clogging the tubular lumen, brown deposits in the cytoplasm of tubular epithelial cells	Hemodialysis	Improvement of kidney function after normalization of bilirubin and hemodialysis
Aniort et al. [41]	61/M	CBD stones induced obstructive jaundice	32.6 (T)	5.3	Bilirubin tubular casts predominated in distal tubules	ERCP, cholecystectomy	Kidney function fully recovered to Cr level of 0.9 mg/dL after 3 months

ATN acute tubular necrosis, CBD common bile duct, Cr creatinine, D direct, EBV Epstein-Barr virus, ECAD extracorporeal albumin dialysis, ERCP endoscopic retrograde cholangiopancreatography, F female, M male, MARS molecular absorbent recirculating system, NA not available, SPAD single pass albumin dialysis, TCF 2 transcription factor 2, T total

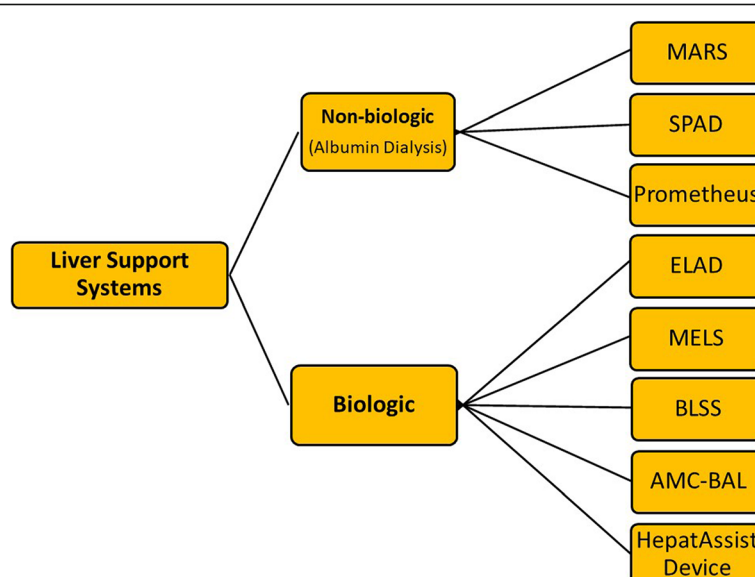
Albumin dialysis is based on the removal of unwanted albumin-bound and water-soluble substances such as bilirubin, bile acids, and other hepatotoxins which are mostly albumin bound [44]. It can take place in two forms: molecular absorbent recirculating system (MARS) and single pass albumin dialysis (SPAD).

MARS consists of two separate dialysis circuits; the first consists of exogenous human albumin in contact with the patient’s blood via a semi-permeable polysulfone membrane while maintaining a constant flow of albumin as dialysate in the extracapillary compartment [44, 45]. A counter-current bicarbonate based dialysate removes water soluble toxins from the toxin enriched albumin solution. Albumin in the dialysate is regenerated by adsorber columns containing activated charcoal and

anion exchange resin [51]. This regenerated albumin dialysate is then recirculated for new uptake of toxins in the blood.

SPAD is a form of venovenous hemodialysis incorporating albumin into the conventional hemodialysis solution [52, 53]. Unlike MARS, the albumin dialysate is not regenerated (single pass) [54]. Sens et al. reported drastic improvement of kidney function in their patient with cholemic nephropathy after one MARS and eight SPAD sessions were performed [26].

MARS was compared to single-pass albumin dialysis (SPAD) in terms of reduction of bilirubin levels and influence on other parameters such as creatinine [55]. Although both systems reduced plasma bilirubin similarly [55], MARS reduced creatinine and bile acids more



**Fig. 2** Extracorporeal therapies



significantly [55]. This might support the role of MARS in bile cast nephropathy.

In spite of suggested improvement with albumin dialysis, these studies were small and hence large scale studies should be conducted to gather more outcome data on this therapeutic technique. Medical therapy using steroids, ursodeoxycholic acid, cholestyramine, or lactulose have little to no benefit in bile cast nephropathy [2].

## Conclusion

Bile cast nephropathy should be kept in mind when approaching a patient with acute renal failure in the setting of hyperbilirubinemia. Several mechanisms such as tubular damage, tubular obstruction, and hemodynamic changes have been proposed to explain kidney injury in patients with bile cast nephropathy. Definitive diagnosis of this entity remains a challenge; nonetheless, there seems to be a promising role for trans-jugular renal biopsy. In the absence of a clear cause of renal injury, one should consider initiating prompt treatment if bile cast nephropathy is suspected. Suggested treatment options include reversal of the cause of liver injury and initiation of albumin dialysis. Studies are lacking whether preemptive treatment with bilirubin lowering therapy can help prevent kidney injury.

## Abbreviations

AKI: Acute kidney injury; ATN: Acute Tubular Necrosis; CBD: Common bile duct; CBDL: Common Bile Duct Ligation; Cr: Creatinine; D: Direct; EBV: Epstein-Barr virus; ECAD: Extracorporeal albumin dialysis; ERCP: Endoscopic retrograde cholangiopancreatography; F: Female; M: Male; MARS: Molecular absorbent recirculating system; NA: Not available; SPAD: Single pass albumin dialysis; T: Total; TCF 2: Transcription factor 2

## Authors' contributions

EA and JK were involved in the acquisition of data (literature), and manuscript writing. KS was involved in the interpretation of data (literature), and revising the manuscript. She also gave her final approval of the version prior to submission. The authors read and approved the final manuscript.

## Funding

Not applicable

## Availability of data and materials

Not applicable

## Ethics approval and consent to participate

Not applicable

## Consent for publication

Not applicable

## Competing interests

The authors declare that they have no potential conflicts of interests.

## Author details

<sup>1</sup>Department of Internal Medicine, American University of Beirut, Beirut, Lebanon. <sup>2</sup>Department of Internal Medicine, Detroit Medical Center/Wayne State University, Detroit, MI, USA. <sup>3</sup>Department of Internal Medicine, Division of Nephrology, Faculty of Medicine, American University of Beirut, PO-BOX: 11-0236, Riad El Solh, Beirut 1107 2020, Lebanon.

Received: 17 July 2019 Accepted: 3 March 2020

Published online: 17 March 2020

## References

- Krones E, Wagner M, Eller K, et al. Bile acid-induced cholemic nephropathy. *Dig Dis*. 2015;33:367–75.
- Patel J, Walayat S, Kalva N, et al. Bile cast nephropathy: a case report and review of the literature. *World J Gastroenterol*. 2016;22:6328–34.
- van Slambrouck CM, Salem F, Meehan SM, et al. Bile cast nephropathy is a common pathologic finding for kidney injury associated with severe liver dysfunction. *Kidney Int*. 2013;84:192–7.
- Alnasrallah B, Collins JF, Zwi LJ. Bile nephropathy in flucloxacillin-induced cholestatic liver dysfunction. *Case Rep Nephrol*. 2016;2016:4162674.
- Romano TG, Vieira Junior JM. Do biliary salts have role on acute kidney injury development? *J Clin Med Res*. 2015;7:667–71.
- Figuerola BE, Brown JR, Nascimento A, et al. Unusual sites of Hodgkin's lymphoma: CASE 2. Hodgkin's lymphoma of the CNS masquerading as meningioma. *J Clin Oncol*. 2004;22:4228–30.
- Nayak SL, Kumar M, Bihari C, et al. Bile cast nephropathy in patients with acute kidney injury due to hepatorenal syndrome: a postmortem kidney biopsy study. *Journal of clinical and translational hepatology*. 2017;5:92–100.
- Chiang JY. Bile acid metabolism and signaling. *Compr Physiol*. 2013;3:1191–212.
- Boyer JL. Bile formation and secretion. *Comprehensive Physiology*. 2013;3:1035–78.
- Bredewold OW, de Fijter JW, Rabelink T. A case of mononucleosis infectiosa presenting with cholemic nephrosis. *NDT Plus*. 2011;4:170–2.
- vdW H, vd B, vd B JG, et al. A 73-year-old male with jaundice and acute kidney injury. *Netherlands J Med*. 2014;72:95–9.
- Alalawi FJ. Bile cast nephropathy secondary to acute transient liver injury and autoimmune haemolytic anaemia: case presentation and review of literatures. *J Nephrol Ther*. 2015;05.
- Holmes TW Jr. The histologic lesion of cholemic nephrosis. *J Urol*. 1953;70:677–85.
- Wolf G, Ziyadeh FN. Molecular mechanisms of diabetic renal hypertrophy. *Kidney Int*. 1999;56:393–405.
- Rafat C, Burbach M, Brocheriou I, et al. Bilirubin-associated acute tubular necrosis in a kidney transplant recipient. *Am J Kidney Dis*. 2013;61:782–5.
- Fickert P, Krones E, Pollheimer MJ, et al. Bile acids trigger cholemic nephropathy in common bile-duct-ligated mice. *Hepatology*. 2013;58:2056–69.
- Krones E, Pollheimer MJ, Rosenkranz AR, et al. Cholemic nephropathy - historical notes and novel perspectives. *Biochim Biophys Acta Mol Basis Dis*. 1864;2018:1356–66.
- Sitpriya V, Kashemsant U, Sriratanaban A, et al. Renal function in obstructive jaundice in man: cholangiocarcinoma model. *Kidney International*. 1990;38:948–55.
- Luciano RL, Castano E, Moeckel G, et al. Bile acid nephropathy in a bodybuilder abusing an anabolic androgenic steroid. *Am J Kidney Dis*. 2014;64:473–6.
- BILLING BH. Twenty-five years of progress in bilirubin metabolism (1952-77). *Gut*. 1978;19:487–91.
- HK SM, Burckhardt G, Gerok W, Knauf H. Sulfated bile acids inhibit Na(+)-H+ antiport in human kidney brush-border membrane vesicles. *Am J Physiol*. 1990;258:F986–91.
- Green JBO. Systemic hypotension and renal failure in obstructive jaundice-mechanistic and therapeutic aspects. *J Am Soc Nephrol*. 1995;5:1853–71.
- Javier Padillo M, Jesús Puente MD, Manuel Gómez MD, Francisco Dios MD, Antonio Naranjo MD, Juan A. Vallejo, MD, Gonzalo Miño, MD, Carlos Pera, MD, and Antonio Sitges-Serra, MD, FRCSEd. Improved cardiac function in patients with obstructive jaundice after internal biliary drainage. *Annals Surg*. 2001;234:652–6.
- Green JBR, Sideman S, Mordechovitz D, Better OS. The "jaundiced heart": a possible explanation for postoperative shock in obstructive jaundice. *Surgery*. 1986;100:14–20.
- Wadei HM, Mai ML, Ahsan N, et al. Hepatorenal syndrome: pathophysiology and management. *Clin J Am Soc Nephrol*. 2006;1:1066–79.
- Sens F, Bacchetta J, Rabeyrin M, et al. Efficacy of extracorporeal albumin dialysis for acute kidney injury due to cholestatic jaundice nephrotoxicity. *BMJ Case Rep*. 2016;2016.

27. Guo SM, Han M, Chen MX, et al. Soluble urokinase receptor levels are correlated with focal segmental glomerulosclerosis lesions in IgA nephropathy: a cohort study from China. *PLoS One*. 2015;10:e0138718.
28. Sequeira A, Gu X. Bile cast nephropathy: an often forgotten diagnosis. *Hemodial Int*. 2015;19:132–5.
29. Song J, Chang A. Jaundice-associated acute kidney injury. *NDT Plus*. 2009;2:82–3.
30. Bal C, Longkumer T, Patel C, et al. Renal function and structure in subacute hepatic failure. *J Gastroenterol Hepatol*. 2000;15:1318–24.
31. Kiewe P, Korfel A, Loddenkemper C, et al. Unusual sites of Hodgkin's lymphoma: CASE 3. Cholemic nephrosis in Hodgkin's lymphoma with liver involvement. *J Clin Oncol*. 2004;22:4230–1.
32. Betjes MG, Bajema I. The pathology of jaundice-related renal insufficiency: cholemic nephrosis revisited. *J Nephrol*. 2006;19:229–33.
33. Uslu A, Tasli FA, Nart A, et al. Human kidney histopathology in acute obstructive jaundice: a prospective study. *Eur J Gastroenterol Hepatol*. 2010;22:1458–65.
34. Tabatabaee SM, Elahi R, Savaj S. Bile cast nephropathy due to cholestatic jaundice after using stanozolol in 2 amateur bodybuilders. *Iran J Kidney Dis*. 2015;9:331–4.
35. Alkhunaizi AM, ElTigani MA, Rabah RS, et al. Acute bile nephropathy secondary to anabolic steroids. *Clin Nephrol*. 2016;85:121–6.
36. Jain K, Gupta A, Singh HK, et al. Bile cast nephropathy. *Kidney Int*. 2015;87:484.
37. Flores A, Nustas R, Nguyen H-L, et al. Severe cholestasis and bile acid nephropathy from anabolic steroids successfully treated with plasmapheresis. *ACG case reports journal*. 2016;3:133–5.
38. Werner CR, Wagner V, Sipos B, et al. Acute kidney injury in liver failure. *Dtsch Med Wochenschr*. 2016;141:1559.
39. Mohapatra MK, Behera AK, Karua PC, et al. Urinary bile casts in bile cast nephropathy secondary to severe falciparum malaria. *Clin Kidney J*. 2016;9:644–8.
40. Leclerc M, Lanot A, Bechade C, et al. Bile salt nephropathy/cholemic nephrosis. *Nephrol Ther*. 2016;12:460–2.
41. Anriort J, Poyet A, Kemeny JL, et al. Bile cast nephropathy caused by obstructive cholestasis. *Am J Kidney Dis*. 2017;69:143–6.
42. Cluzel P, Martinez F, Bellin MF, et al. Transjugular versus percutaneous renal biopsy for the diagnosis of parenchymal disease: comparison of sampling effectiveness and complications. *Radiology*. 2000;215:689–93.
43. Sam R, Leehey DJ, Picken MM, et al. Transjugular renal biopsy in patients with liver disease. *Am J Kidney Dis*. 2001;37:1144–51.
44. Tsiptotis E, Shuja A, Jaber BL. Albumin dialysis for liver failure: a systematic review. *Adv Chronic Kidney Dis*. 2015;22:382–90.
45. Jalan R, Sen S, Steiner C, et al. Extracorporeal liver support with molecular adsorbents recirculating system in patients with severe acute alcoholic hepatitis. *J Hepatol*. 2003;38:24–31.
46. Duan ZJ, Li LL, Ju J, et al. Treatment of hyperbilirubinemia with blood purification in China. *World J Gastroenterol*. 2006;12:7467–71.
47. Tayama E, Kashiki H, Hayashida N, et al. Plasma exchange for hyperbilirubinemia following implantation of a left ventricle assist system: a case report. *Jpn Circ J*. 2000;64:455–8.
48. Keklik M, Sivgin S, Kaynar L, et al. Treatment with plasma exchange may serve beneficial effect in patients with severe hyperbilirubinemia: a single center experience. *Transfus Apher Sci*. 2013;48:323–6.
49. Demeulenaere L, Barbier F, Vermeire P. Plasmapheresis in hepatic coma. *Lancet*. 1969;1:152–3.
50. El Khoury C, Sabbouh T, Farhat H, et al. Severe cholestasis and bile cast nephropathy induced by anabolic steroids successfully treated with plasma exchange. *Case Rep Med*. 2017;2017:4.
51. Inderbitzin D, Muggli B, Ringger A, et al. Molecular adsorbent recirculating system for the treatment of acute liver failure in surgical patients. *J Gastrointest Surg*. 2005;9:1155–61 discussion 1161–2.
52. Boonsrirat U, Tiranathanagul K, Srisawat N, et al. Effective bilirubin reduction by single-pass albumin dialysis in liver failure. *Artif Organs*. 2009;33:648–53.
53. Chawla LS, Georgescu F, Abell B, et al. Modification of continuous venovenous hemodiafiltration with single-pass albumin dialysate allows for removal of serum bilirubin. *Am J Kidney Dis*. 2005;45:e51–6.
54. Podoll AS, DeGolovine A, Finkel KW. Liver support systems—a review. *ASAIO J*. 2012;58:443–9.
55. Sponholz C, Matthes K, Rupp D, et al. Molecular adsorbent recirculating system and single-pass albumin dialysis in liver failure—a prospective, randomised crossover study. *Crit Care*. 2016;20:2.

## Publisher's Note

Springer Nature remains neutral with regard to jurisdictional claims in published maps and institutional affiliations.

**Ready to submit your research? Choose BMC and benefit from:**

- fast, convenient online submission
- thorough peer review by experienced researchers in your field
- rapid publication on acceptance
- support for research data, including large and complex data types
- gold Open Access which fosters wider collaboration and increased citations
- maximum visibility for your research: over 100M website views per year

**At BMC, research is always in progress.**

Learn more [biomedcentral.com/submissions](https://www.biomedcentral.com/submissions)

